

GENERAL OBSTETRICS

## Operative vaginal delivery: clinical appraisal of a new vacuum extraction device

Aldo Vacca

*Caboolture and Redcliffe Hospitals, Caboolture, Queensland, Australia*

### SUMMARY

The efficacy of a new vacuum extraction device, the Kiwi OmniCup, and its effects on mothers and infants were tested in a study of 18 non-rotational and 32 rotational vacuum assisted deliveries. Forty-nine (98%) of the extractions resulted in successful vaginal births. Autorotation of the fetal head when the occiput was transverse or posterior was achieved in 31 (97%) of the 32 vacuum procedures. The high success rates recorded for both vaginal delivery and autorotation of the fetal head were largely attributable to the fact that flexing cup applications were achieved in 90% of the vacuum attempts.

There were no cases of serious maternal trauma or clinically significant neonatal injuries. Two infants had cephalohaematomas and one infant developed a small subgaleal haemorrhage following a difficult delivery, which resolved rapidly without complications.

It was concluded that the Kiwi OmniCup is an efficient and safe vacuum device for assisted vaginal delivery, provided it is used correctly and appropriately.

### INTRODUCTION

Essentially, all vacuum extraction devices consist of a cup made of soft or rigid material which can be attached to the fetal scalp, a vacuum pump that provides suction for the cup's attachment and a traction system that allows the operator to assist the mother with the birth. Consistently good results with the vacuum extractor, however, depend upon achieving correct applications of the cup on the fetal scalp.<sup>1</sup> Unfortunately, the design of many of the cups currently in use makes it difficult and sometimes impossible to achieve a correct cup application when the fetal head is malpositioned, particularly when deflexion and asynclitism are present.<sup>2</sup> The Kiwi OmniCup Vacuum Delivery System™ (Clinical Innovations Inc, Murray, Utah, USA) is a new vacuum extraction device that incorporates Bird's 'posterior cup' concept<sup>3</sup> which should make the cup suitable for use not only in occipitoanterior positions but also in transverse and posterior positions of the occiput.

The primary objectives of the present study were to evaluate the efficacy of the OmniCup for rotational and non-rotational vacuum delivery and to assess the

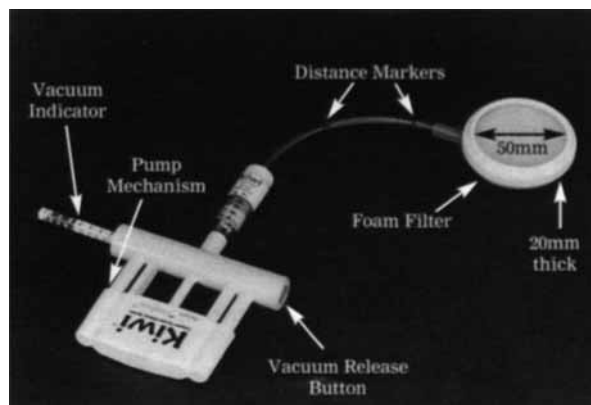
maternal and fetal effects of the device in clinical practice.

### MATERIALS AND METHODS

#### Features of the OmniCup

The standard OmniCup vacuum device is a low profile, Malmstrom-design cup with a thin flexible suction tube through which passes a traction wire that is attached to the centre of the dome of the cup (Figure 1). It is made from a rigid plastic material and is designed for single patient use only. The device

**Figure 1** The Kiwi OmniCup vacuum extractor incorporating a traction force gauge



Address for correspondence

Dr Aldo Vacca  
PO Box 614  
Albion Queensland 4010 Australia

Aldo Vacca Director of Obstetric Services

incorporates a lightweight and compact PalmPump™ vacuum mechanism which provides the suction for cup attachment to the fetal scalp and also serves as a handle for traction.

The PalmPump cylinder houses a colour-coded vacuum indicator gauge that displays the amount of generated suction as well as a valve for releasing the pressure. Measurement indicators on the suction tubing assist the operator to determine that the cup has been inserted a sufficient distance into the birth canal to be correctly placed over the flexion point. In addition, there is a model of the OmniCup that includes a traction force indicator which permits the operator to view and control the amount of traction that is being exerted on the fetal scalp.

The OmniCup may be used as an 'anterior' cup for occipitoanterior and outlet procedures by direct application of the cup to the fetal head. The device functions as a 'posterior' cup suitable for use in occipitotransverse and posterior positions when the cup is manoeuvred into the birth canal with the suction tube recessed in a groove on the dome of the cup.

### Study population

Fifty vacuum extractions comprising 32 low and 18 mid-cavity deliveries attempted at Caboolture Hospital between January and December 1999 were analysed. Eligibility criteria were term gestation, a valid indication for expediting birth and obstetric circumstances assessed to be appropriate for vacuum extraction. Women who fulfilled the selection criteria were informed of the study and the deliveries were conducted according to standard hospital protocol.

Twenty-five of the vacuum extractions were undertaken by obstetricians and 25 by obstetric registrars, usually under supervision. When the operators were satisfied that the cup was correctly positioned on the fetal scalp, the vacuum pressure was increased to 600 mm Hg in one step and maintained at this level throughout the procedure until the head was delivered. In 30 vacuum extractions, the OmniCup incorporated a traction force indicator which provided a means of recording the maximum traction force attained in these deliveries. In no case was traction applied to the fetal scalp between contractions to prevent loss of station of the head.

The operator completed a data form as soon as possible after the delivery. Details were collected about the technical aspects of each procedure including difficulty, cup application site, number of tractions, duration of the procedure and, in fetal malpositions, whether anterior rotation of the occiput occurred. On the day after the delivery, the author or a study coordinator examined each baby's scalp to record any injury associated with the vacuum extraction. All of the infants who sustained injuries attributable to the delivery were reviewed at regular intervals by the author following discharge from hospital until complete resolution of the lesions had occurred.

## RESULTS

The average age of the 44 nulliparous and six multiparous women was 25.3 years. The mean gestational age and standard deviation of the newborn infants was  $40 \pm 1.2$  weeks. Analgesia for the deliveries was provided by epidural regional block in 27 women and perineal infiltration in 19. No analgesia was required for four of the women. Primary indications for assisted delivery and the stations and positions of the fetal head at the time of cup application are shown in Table 1. Eighteen extractions were attempted from mid-pelvic stations and 32 were rotational procedures. The mean birthweight and standard deviation of the infants was  $3527 \pm 534$  g.

**Table 1** Primary indications and obstetric characteristics

	OmniCup deliveries n = 50
<b>Primary indications</b>	
Arrest of descent	33
Non-reassuring fetal status	13
Preeclampsia	3
Maternal heart condition	1
<b>Duration of second stage</b>	
Mean (min) $\pm$ standard deviation	$112 \pm 30$
<b>Station of the head</b>	
Low (+2 to +4 cm)	32
Mid (0 to +1 cm)	18
<b>Position of the head</b>	
Occipitoanterior (< 45° rotation)	18
Occipitotransverse (incl > 45°)	21
Occipitoposterior	11

Procedural details regarding the efficacy of the OmniCup are shown in Table 2. Successful vaginal delivery was achieved in all of the extractions attempted when the fetal head was occipitoanterior and in 97% of the deliveries when the occiput was transverse or posterior. The vacuum extraction that failed occurred in a nulliparous woman who had been pushing for longer than one hour in the second stage of labour. The fetal head was stationed in the mid-pelvis (+1 cm) and the position was occipitoposterior. Descent of the head to the level of the pelvic outlet was achieved in five pulls but detachment of the cup occurred on the perineum and delivery was completed with forceps with the fetal head remaining in a persistent occipitoposterior position. The infant's birthweight was 3690 g. The site of application of the cup on the scalp was recorded as deflexing and paramedian. There was no trauma to the scalp caused by the extraction and, apart from episiotomy, no maternal genital tract injury.

The number of pulls required for the deliveries are shown in Table 2. Overall, 86% of the extractions were completed in four or fewer pulls but the number var-

ied with station and position of the fetal head and whether the application of the cup was flexing or deflexing. Five pulls or more were required for delivery in 29% of the mid-pelvic extractions, and in 16% of the rotational procedures and 40% where the cup application was deflexing. On the other hand, when the procedure was low, non-rotational or associated with a flexing cup application the corresponding rates were 6%, 11% and 11% respectively.

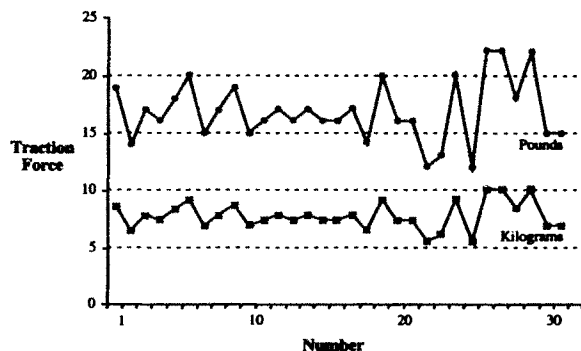
**Table 2** Vacuum extraction procedural details

	OmniCup deliveries n = 50
<b>Method of delivery:</b>	
Successful vacuum delivery	49
Failed vacuum (forceps delivery)	1
<b>Vacuum cup application</b>	
Flexing	45
Deflexing	5
<b>Number of pulls</b>	
< 4 pulls	43
> 5 pulls	7
<b>Duration of the procedure</b>	
< 15 min	48
> 15 min	2
<b>Anterior rotation from OT / OP:</b> (n = 32)	
Rotation to OA	31
Failure of rotation to OA	1

OA = occipitoanterior, OT = occipitotransverse, OP = occipitoposterior

The maximum traction force registered during 30 of the vacuum extractions is shown in Figure 2. All of the deliveries were successfully accomplished without the traction force exceeding 10 kg and without detachment of the cup. Apart from a transient parietal cephalohaematoma in one infant in this group, no scalp injuries were reported.

**Figure 2** The maximum traction force registered in 30 vacuum extractions



All but two of the 50 vacuum extractions were completed within 15 minutes from the time of applying the cup to the fetal head (Table 2). The two

extractions that extended beyond 15 minutes were rotational mid pelvic procedures of which one resulted in failed vacuum extraction and the other in scalp injury. The average time interval from cup application to delivery was 6.5 minutes for non-rotational procedures and 8.8 minutes for rotational deliveries.

Flexing applications of the vacuum cup were recorded in 45 (90%) of the total number of vacuum deliveries. When analysed in relation to positions of the occiput, flexing applications were achieved in 94% of the 18 occipitoanterior extractions and in 86% of 21 occipitotransverse and 91% of 11 occipitoposterior deliveries. Rotation of the fetal head to occipitoanterior position (autorotation) occurred in 31 (97%) of the 32 extractions attempted when the occiput was transverse or posterior. In the single case of failed autorotation, the application of the cup was recorded as deflexing.

Vacuum delivery was accomplished with intact perineum in nine women and with second degree perineal lacerations in four. Right mediolateral episiotomy was performed electively for the delivery in 36 of the women. One episiotomy extended to include the anal sphincter but did not involve the anal or rectal mucosa.

To some degree, all infants had cup markings on the scalp but they were transient and usually disappeared within 72 hours of the birth. Fetal electrodes were attached to the scalp in 35 of the infants during labour and scalp blood sampling for pH estimation was obtained in nine. Two infants developed superficial scalp blisters following vacuum delivery and one sustained a laceration measuring 2 cm along the perimeter of the cup mark.

Parietal cephalohaematomas were recorded in two infants and a small subgaleal haemorrhage developed in one. The mother of the infant who developed the subgaleal haematoma was a nullipara who had a prolonged second stage of labour lasting 170 minutes and who had been pushing for about 90 minutes without significant descent of the head. Fetal position was occipitotransverse and the station of the head was assessed to be at the level of the ischial spines. The vacuum cup was applied correctly to the fetal scalp and slow descent was achieved over eight contractions. Duration of the vacuum extraction was 21 minutes and the birth was complicated by shoulder dystocia. The infant's birthweight was 4620 g.

Scalp blisters were no longer visible by the end of the first week following discharge from hospital and the laceration of the scalp was healed by the end of the second week. Complete resolution of the cephalohaematomas occurred between the second and fifth week and the subgaleal haemorrhage had resolved by the third postpartum day without complication other than jaundice that required phototherapy. The infant was normal when reviewed at the six weeks postpartum check.

## DISCUSSION

A vaginal delivery rate of 98% for the 50 vacuum extractions attempted with the OmniCup compares favourably with efficacy rates reported in previous studies of rigid cup vacuum deliveries.<sup>2,4,5,6</sup> The performance of the device was also noteworthy for the successful management of cases of malposition of the fetal head, where only one failure was recorded in 32 of the rotational deliveries. A number of predisposing factors have been linked to unsuccessful vacuum extraction and failure of autorotation.<sup>7</sup> Arguably, the most common of these is incorrect application of the vacuum cup on the fetal scalp. Unfortunately, many of the cups in current use have semi-rigid stems or handles attached at the dome of the cup, which restricts the movement of the device within the limited space of the birth canal and makes correct applications difficult to achieve in transverse and posterior positions of the occiput.<sup>2</sup>

In this study the increased manoeuvrability of the OmniCup was demonstrated by the high rate of flexing cup applications recorded in the cases of malposition of the fetal head. It is likely that this feature was a major contributing factor to the favourable results achieved by the OmniCup.

The OmniCup model incorporating a traction force gauge provided an opportunity to record maximum traction forces exerted on the scalp during vacuum extraction. Investigators have in the past attempted to define what forces constitute safe levels of traction and compression during operative vaginal delivery.<sup>8,9</sup> The upper limits of safety are not known but a traction force of 23 kg has been suggested.<sup>10</sup>

In the Caboolture study, all 30 vacuum deliveries where recording was undertaken were successfully accomplished using traction forces that remained well below the suggested maximum safety levels. At the commencement of the study, measuring the traction force was an information-gathering exercise but later it became an integral part of vacuum extraction technique. This represented a slight conceptual shift away from current teaching on vacuum delivery because restriction in the number of pulls is the principal safety mechanism recommended for avoiding injury to the newborn infant. Nevertheless, in spite of the limitation on the amount of traction employed for the delivery, 86% of the vacuum extractions were completed using four pulls or fewer and 96% of the infants were delivered within 15 minutes of applying the cup to the fetal head.

There was a perception among operators when the OmniCup was first introduced that the PalmPump was too small to provide adequate vacuum for delivery but this was shown to be incorrect. Adhesive and traction forces are dependent upon pressure not volume and the PalmPump was quite capable of generating the required traction force (sufficient vacuum) to deliver the fetus in about 10 squeezes. Only one detachment of the cup was recorded and this was associated

with a deflexing application of the cup. A noteworthy practical feature of the device was that, prior to detachment, loss of vacuum was signalled by the pressure gauge emerging from within the PalmPump cylinder. This finding was later incorporated into vacuum extraction practice at Caboolture hospital as a warning sign of imminent detachment. If the gauge moved, the operator immediately discontinued traction while quickly restoring the pressure to the operating level with a few squeezes of the palm pump. Another unexpected but important finding was that the pump mechanism continued to function even when liquid was drawn into the chamber.

None of the scalp injuries attributable to the vacuum deliveries resulted in clinically significant adverse outcomes for the infants during the neonatal period or in the weeks following the delivery. The subgaleal haematoma had the potential for greater morbidity but in the case reported here, complete resolution occurred within a few days of the birth. Not surprisingly, the subgaleal haemorrhage was associated with a difficult vacuum delivery.<sup>11</sup> All three infants who developed bleeding into the scalp following vacuum extraction (2 cephalohaematomas, 1 subgaleal haemorrhage) had electrodes applied to the scalp for continuous monitoring during labour. However, 32 other infants also had electrodes attached to the scalp and nine of them had fetal scalp blood sampling performed for pH estimation. None of these infants developed cephalohaematomas. These findings indicate that the incidence of bleeding into the scalp is not increased when vacuum extraction is used following scalp electrode application and fetal blood sampling.

In summary, the results of this study of 50 vacuum assisted deliveries suggest that the OmniCup is an efficient and safe device that is suitable for use in rotational and non-rotational vacuum extractions. However, selection of patients, correct technique and adherence to safety rules also influence the outcomes and therefore should be taken into consideration when assessing the performance of the device. In the present study, avoidable factors were identifiable in the vacuum extraction that failed and in the vacuum delivery that resulted in subgaleal haemorrhage.

## REFERENCES

- 1 Bird GC. The use of the vacuum extractor. *Clin Obstet Gynaecol* 1982; 9: 641-661.
- 2 Johanson R, Menon V. Soft versus rigid vacuum extractor cups for assisted vaginal delivery. In: *The Cochrane Library*, Issue 3, 2000. Oxford: Update Software.
- 3 Bird GC. The importance of flexion in vacuum extraction delivery. *Br J Obstet Gynaecol* 1976; 83: 194-200.
- 4 Johanson R, Menon V. Vacuum extraction vs forceps delivery. In: *The Cochrane Library*, Issue 3, 2000. Oxford: Update Software.
- 5 Vacca A, Grant A, Wyatt G, Chalmers I. Portsmouth operative delivery trial: a comparison of vacuum extraction and forceps delivery. *Br J Obstet Gynaecol* 1983; 90: 1107-1112.
- 6 Boffill JA, Rust OA, Schorr SJ, et al. A randomized prospective trial of the obstetric forceps versus the M-cup vacuum extractor. *Am J Obstet Gynecol* 1996; 175: 1325-1330.

- 7 Vacca A. The trouble with vacuum extraction. *Current Obstet Gynaecol* 1999; 9: 41-45.
- 8 Pearse WH. Electronic recording of forceps delivery. *Am J Obstet Gynecol* 1963; 86: 43-49.
- 9 Duchon MA, De Mund MA, Brown RH. Laboratory comparison of modern vacuum extractors. *Obstet Gynecol* 1988; 71: 155-158.
- 10 Moolgaoker AS, Ahamed SO, Payne PR. A comparison of different methods of instrumental delivery based on electronic measurements of compression and traction. *Obstet Gynecol* 1979; 54: 299-309.
- 11 Fortune PM, Thomas RM. Sub-aponeurotic haemorrhage: a rare but life-threatening neonatal complication associated with ventouse delivery. *Br J Obstet Gynaecol* 1999; 106: 868-870.